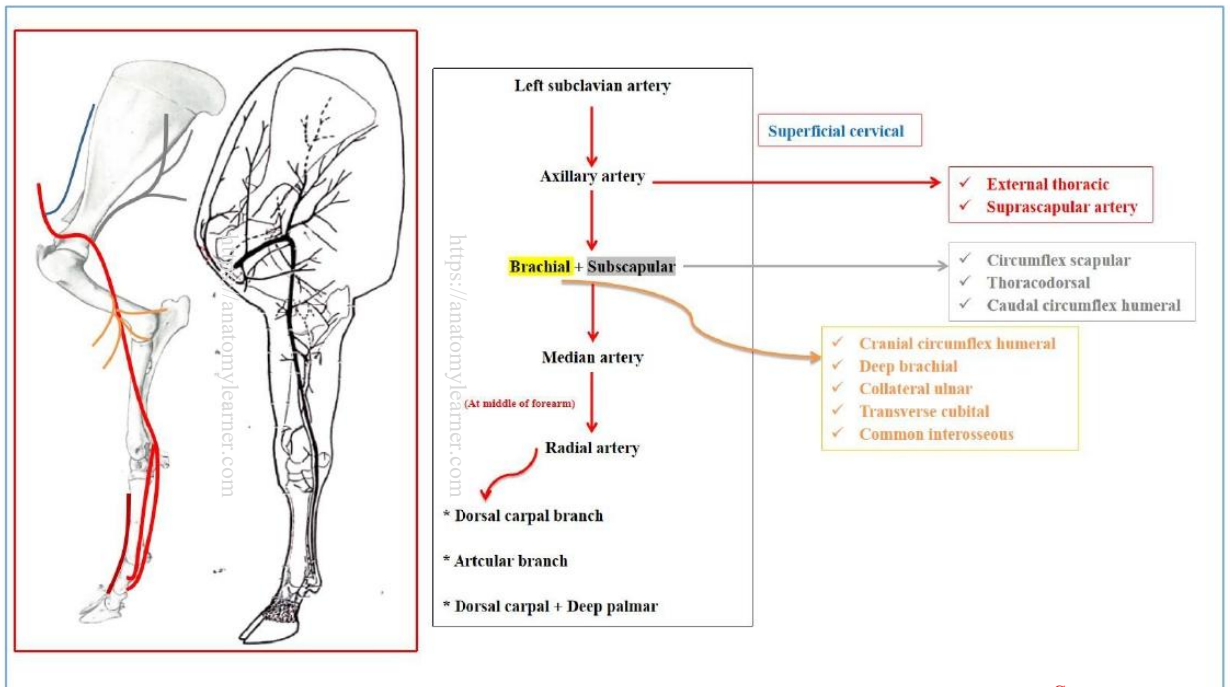
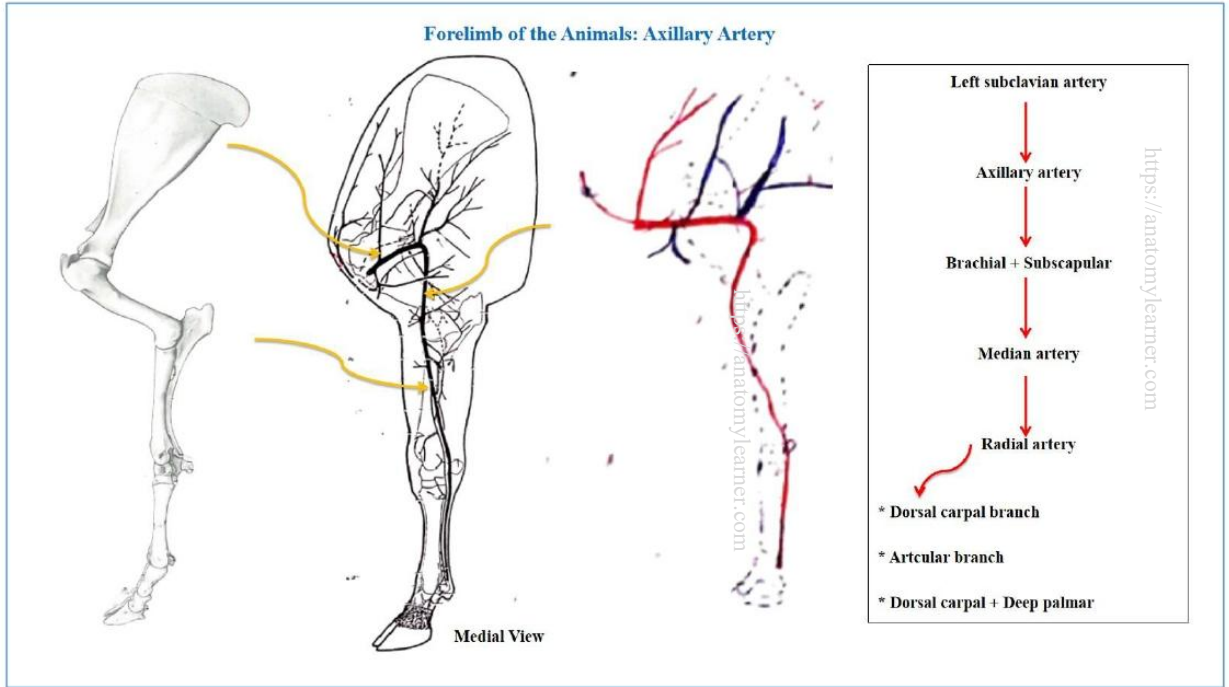


This document is not intended to serve as a complete resource for studying the course and anatomy of the Axillary Artery and External Iliac Artery. For comprehensive learning, students are advised to attend practical and theoretical classes and consult the prescribed textbooks. Thank you

[Check for updates]

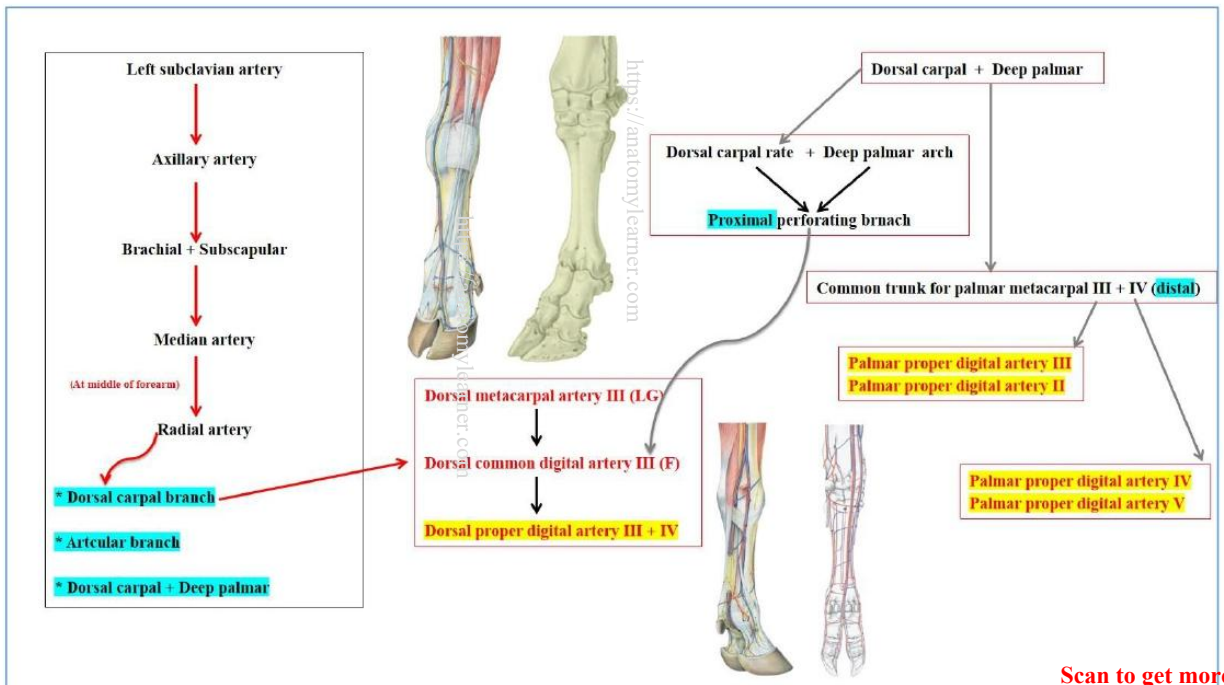
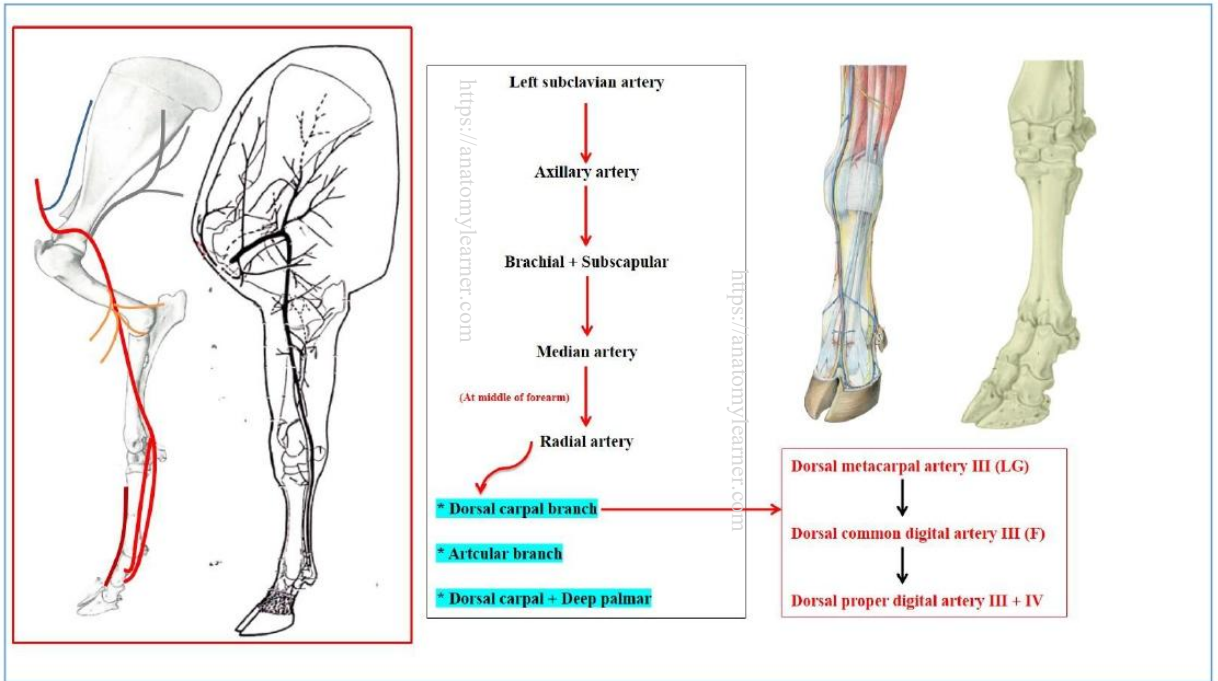


Scan to get more notes



This document is not intended to serve as a complete resource for studying the course and anatomy of the Axillary Artery and External Iliac Artery. For comprehensive learning, students are advised to attend practical and theoretical classes and consult the prescribed textbooks. Thank you

[Check for updates]



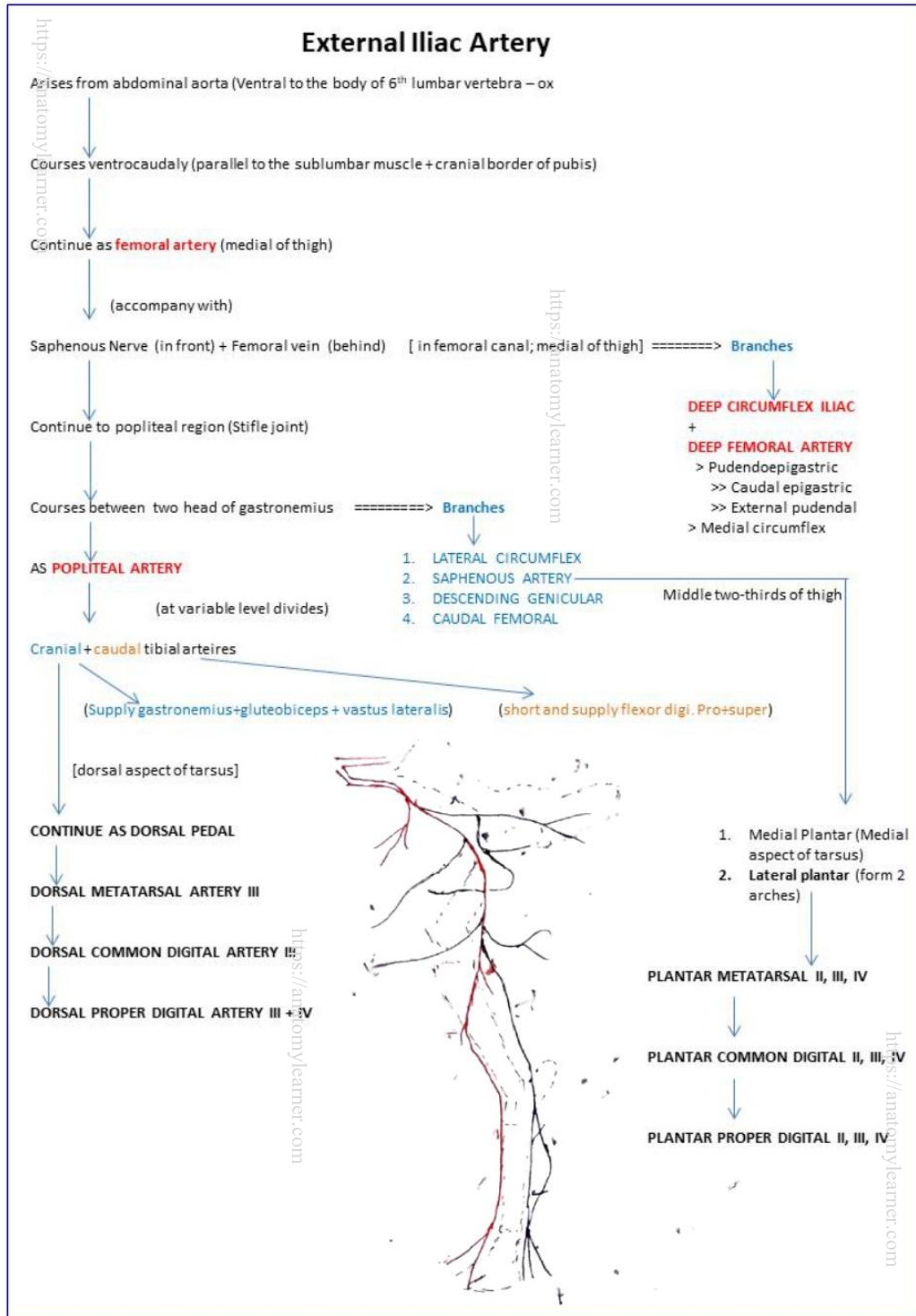
Scan to get more notes



This document is not intended to serve as a complete resource for studying the course and anatomy of the Axillary Artery and External Iliac Artery. For comprehensive learning, students are advised to attend practical and theoretical classes and consult the prescribed textbooks. Thank you

https://anatomylearner.com

[Check for updates]



Scan to get more notes



https://anatomylearner.com

https://anatomylearner.com

https://anatomylearner.com